

REVIEW

Patterns and predictors of atypical language representation in epilepsy

Krijn Kristian Dijkstra,¹ Cyrille Henri Ferrier²

¹University Medical Center Utrecht, University of Utrecht, Utrecht, The Netherlands
²Rudolf Magnus Institute of Neuroscience, Department of Neurology & Neurosurgery, University Medical Center Utrecht, University of Utrecht, The Netherlands

Correspondence to

Dr Cyrille Henri Ferrier, Rudolf Magnus Institute of Neuroscience, University Medical Center Utrecht, Neurology & Neurosurgery F02.2.30, Heidelberglaan 100, 3584 CX Utrecht, The Netherlands; cferrier@umcutrecht.nl

Received 6 May 2012

Revised 14 July 2012

Accepted 1 August 2012

Published Online First

1 September 2012

ABSTRACT

In the majority of the normal population, the left hemisphere is dominant for language. In epilepsy, a higher proportion of 'atypical' language representation is encountered. This can follow one of three patterns: (1) altered interhemispheric representation, where the spectrum of lateralisation is shifted to the right; (2) interhemispheric dissociation of linguistic subfunctions; or (3) intrahemispheric changes in representation. Knowledge of these patterns is essential for avoiding postoperative language deficits in epilepsy patients undergoing surgery. Several predictors of atypical language representation exist. It is more prevalent in left-handed individuals. Lesions in rough proximity to classical language areas are more associated with atypical language, although in some cases, remote lesions, such as in the hippocampus, can also lead to altered language representation. The more disruptive the lesion, the more likely atypical language is to be found. Widespread and frequent interictal epileptiform discharges are also associated with atypical language. Atypical language representation is more likely to be present when injury or epilepsy onset occurred at a young age. Thus, a subgroup of patients can be defined in whom atypical language representation is more likely to be found.

INTRODUCTION

For patients with medically intractable epilepsy, surgery may be a viable option. Preoperative mapping of cortical functions is essential to avoid postoperative functional deficits. This is especially true for functions that are represented focally and unilaterally, such as language. In the large majority of the population, language is represented in the left hemisphere in two well-defined areas (Broca's area in the inferior frontal gyrus and Wernicke's area in the superior temporal gyrus). In epilepsy patients, however, atypical language representation is frequently encountered. This can include abnormal representation within the language-dominant hemisphere, or atypical lateralisation. An understanding of the variety of patterns of language representation that can be encountered provides fundamental information on the cerebral organisation of language networks. Moreover, it is of direct interest to the neurosurgeon who should be aware of the possible patterns of language representation in epilepsy to avoid postoperative language deficits. Atypical language representation is encountered more frequently in epilepsy patients than in the normal population, but can also be found in several types of pathology that are not

necessarily associated with seizures, such as tumours, stroke or congenital lesions. Epilepsy is a suitable and interesting model to study plasticity as it occurs relatively frequently, is often present at a young age and interferes with normal brain function in a unique way.

Although atypical language may occur in epilepsy patients, most patients show typical language representation. Predictors of atypical language could aid the clinician in estimating how likely it is for a patient to have atypical language representation, and to what extent language localisation should be carried out, using imaging or invasive techniques. Moreover, although causal relationships are impossible to infer due to the retrospective nature of most studies in this field, predictors of atypical language can provide clues as to why atypical language representation is found in some brains, but not in others.

The first half of this review will deal with the various patterns of language representation that can be encountered. The second half will consider evidence for various factors associated with atypical language, including handedness, lesion location, pathology, epileptic activity and age at onset of epilepsy.

THE NORMAL STATE

Classically, the left hemisphere is considered to be dominant for language in 90%–95% of the population, with bilateral or right hemisphere dominance in the other 5%–10%.^{1,2} Nevertheless, imaging studies have suggested that bilateral processing of language is more common than previously thought, for example, when semantic processing is involved.³ The classification of individuals as 'left-dominant', 'right-dominant' or 'bilateral' always depends on arbitrarily defined cut-off values regarding the *ratio* of left to right hemisphere activation. In an fMRI study of healthy individuals, nearly all participants showed at least some bilateral activation in a semantic decision task.¹ In a verbal fluency task, a spectrum of lateralisation indices was revealed using functional transcranial Doppler ultrasonography; left hemisphere dominance was most common, but many participants yielded weaker lateralisation indices, indicative of a more bilateral response.² It is possible that individuals with atypical language representation are seemingly normal, but have undetected brain abnormalities that may or may not become apparent later in life. This is a difficult point to address as longitudinal studies involving healthy individuals with atypical language representation have not been carried out. However, in healthy volunteers with

atypical language representation there were no differences in academic achievement, IQ or performance on a word generation and picture-word verification task, suggesting atypical language representation can also be found in individuals in whom there is no reason to suspect brain pathology.⁴

PATTERNS OF ATYPICAL LANGUAGE REPRESENTATION

Atypical lateralisation

Many studies have shown that the typical left-dominant language representation is less frequently found in epilepsy patients.^{5–6} In an fMRI study, 94% of normal participants were considered left-dominant and 6% showed bilateral representation. In contrast, 78% of epilepsy patients were left-dominant, 6% right-dominant and 16% showed bilateral activation.¹ Much of our knowledge on language lateralisation is derived from the Wada test, in which the injection of amobarbital in one of the carotid arteries temporarily anaesthetises one hemisphere. If anaesthesia of one hemisphere results in language errors, language is thought to reside in that hemisphere. In a Wada study with a large group of epilepsy patients, 22% had bilateral or right-dominant speech⁷ and fMRI studies report right-dominant language representation in as many as 22%–33% of patients.⁶ A recent ERP study of patients with Rolandic epilepsy showed that right hemisphere dominance may persist even after remission of the disease.⁸ There is some evidence that the right hemisphere brain areas activated in language tasks differ slightly from their left hemispheric counterparts,^{9–10} although other reports challenge this conclusion.¹¹ In patients with atypical language, right hemisphere homologues showed increased activity and increased grey matter volume.¹²

The increase in right-dominant as well as bilateral representation implies that the *spectrum* of language lateralisation is shifted to the right in epilepsy patients. Of note, it is unclear whether this atypical activation represents *compensation* or *reorganisation*.⁵ Considering that some bilateral activity is often present in healthy individuals, impairment of the dominant hemisphere may recruit areas in the subdominant hemisphere with a latent capability to support language (compensation). Alternatively, rewiring of areas previously uninvolved in language processing may occur (reorganisation).

Interestingly, when performing the Wada test on patients with bilateral language representation, some can still perform a given language task regardless of which hemisphere is anaesthetised, while others cannot perform the task with the disruption of either hemisphere.^{7–13} In the former group bilateral representation is redundant, while in the latter, language function is dependent on the integrity of both hemispheres. As disruption studies are rarely performed in healthy volunteers, it is unknown whether these two categories of bilateral representation also exist in the healthy population.

'Crossed dominance'

Areas involved in receptive and productive language (Wernicke's and Broca's area, respectively) are generally considered to reside in the same hemisphere, and when interhemispheric shifts occur, both areas are transferred to the contralateral hemisphere in the large majority of cases. In epilepsy, however, occasional cases of interhemispheric dissociation of language have been observed.

In a large Wada study, four cases (2.8% of the total sample) were described in which two language tasks were dissociated: (1) spontaneous speech (series repetition) and (2) language comprehension.¹⁴ Upon anaesthesia of one hemisphere, patients showed disruption of task (1) but not task (2), while the pattern was reversed when the opposite hemisphere was anaesthetised.

Similar cases of interhemispheric dissociation have been reported in other Wada, functional MRI and magnetoencephalography (MEG) studies.^{13–15–21} Usually, more than one language task is necessary to differentiate between patients with unilateral and discordant receptive and productive language.^{16–22}

Most authors agree that interhemispheric dissociation is rare, occurring in <5% of epilepsy patients.^{13–15–17–21} However, in some studies, rates ranging from 16% to 35% were reported.^{16–18–20} This discrepancy may be due to the use of different definitions of interhemispheric dissociation,^{13–19} and to the fact that imaging studies reveal areas that *participate* in a task, while the Wada test identifies hemispheres that are *essential* for a task. Indeed, higher rates of discordance were reported in fMRI and MEG studies^{18–20} than in Wada studies.^{13–15}

Bilateral representation of one linguistic subfunction and unilateral representation of another can also be found in the normal population.³ This could be defined as interhemispheric dissociation, but it is not known how often it occurs. Conceivably, therefore, the interhemispheric dissociation found in epilepsy could reflect either normal variation or be associated with pathology. Nevertheless, a complete left–right dissociation of linguistic subfunctions has not been reported in the normal population, implying that it is associated with brain pathology.

The possibility of interhemispheric dissociation raises questions about interhemispheric connectivity of language areas and their possible reorganisation. Furthermore, cross-hemispheric representation should be investigated in both patients and healthy controls.

Intrahemispheric changes in language representation

Much of the evidence for intrahemispheric changes in language representation in epilepsy comes from surgery candidates who have undergone invasive electrical stimulation mapping of eloquent cortex.^{23–24} The precise details of localisation exceed the scope of this review, but have been reviewed recently.⁶ Briefly, the mapping of receptive and productive language generally corresponds to traditional language areas (Broca's and Wernicke's area), but also extends beyond these regions. It has therefore been suggested that, in epilepsy, language representation can be displaced from its traditional sites (figure 1). However, since electrical stimulation mapping is not carried out in healthy individuals, it is impossible to conclude that this dispersion of language sites is not reflective of normal variability.

Imaging studies are non-invasive and can therefore serve this purpose. Healthy individuals show considerable inter-subject variability in the precise localisation of language.^{11–25} Whether or not this variability presents itself in group analyses depends on a number of factors, including sample size and statistical thresholds.^{18–25} Nevertheless, there is modest evidence that this variability is larger in epilepsy patients, suggesting that additional (non-traditional) areas are recruited.¹¹ Moreover, it has been shown that areas bordering lesions in typical language sites can be activated in a language task.²⁶

A disadvantage of comparing activation patterns of two predefined groups is that individual heterogeneity is lost. This problem was circumvented by using a data-driven sorting approach to identify subpatterns of activation in patients.¹⁸ Four subgroups were identified: two with prominent right hemisphere activation, one with increased left hemisphere activation in the same areas as controls, and one with different activation clusters in the left temporal lobe. The last group represents patients that recruit alternative intrahemispheric areas.

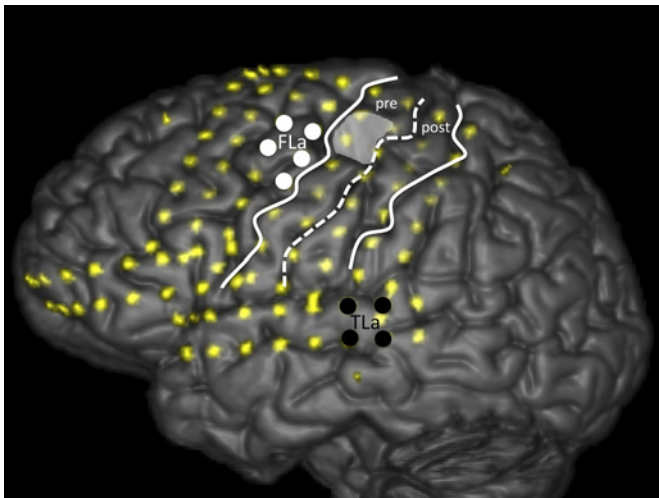


Figure 1 3D MRI surface rendering that shows the positions of subdurally implanted electrodes (vague yellow dots) of a 27-year-old patient with refractory epilepsy due to a ganglioglioma in the left precentral gyrus (shaded grey area). The precentral gyrus (pre) and postcentral gyrus (post) and central sulcus (dashed white line) are marked. Electrocortical stimulation is carried out while the patient performed language tasks. Electrical stimuli consisted of trains (7 s duration) of monophasic pulses (50 Hz, pulse width 0.2 msec, 6 mA). Reproducible errors were induced by electrocortical stimulation of adjacent electrodes during picture naming and reading aloud in two discrete areas. A frontal language area (FLa) was identified by stimulating electrodes on the posterior part of the medial frontal gyrus (white solid dots). A temporal language area (TLa) was identified by stimulating electrodes on the posterior part of the superior temporal gyrus (black solid dots). Language errors were not due to impairment of motor (mouth/tongue) function or after discharges. No errors occurred on similar tasks when stimulating electrodes in the lateral inferior frontal area where Broca's area would traditionally be expected. In this case, the FLa (Broca) appears to be shifted cranially while the localisation of the TLa (Wernicke) is unaltered.

Another group used a data-driven sorting approach with both patients and controls.¹⁰ Three subgroups were identified: (1) activation in areas that broadly correspond to Broca's and Wernicke's area; (2) activation in their right hemisphere homologues; and (3) increased activation in the same areas as group 1, as well as additional activation in the left medial frontal gyrus, left supplementary motor cortex and right cerebellum. Group 1 consisted mostly of controls, groups 2 and 3 mostly of patients. Again, group 3 provides evidence for intrahemispheric changes in language representation in epilepsy.

It cannot be determined whether the additionally recruited sites in the left hemisphere represent reorganisation or compensation. Considering that the groups representing intrahemispheric changes also showed *increased* activation relative to controls,^{10 18} it is possible that at least some of the activation represents compensation.

FACTORS ASSOCIATED WITH ATYPICAL LANGUAGE REPRESENTATION

Not all epilepsy patients have atypical language representation. It is therefore interesting to identify which factors predict atypical language representation (table 1), although a word of caution is necessary. Epilepsy is a highly heterogeneous disorder and patients differ in many aspects both within and between studies, making it difficult to isolate the effect of a particular factor and to compare different studies. Moreover, sample sizes

are usually too small for multivariate analysis. For these reasons, it is impossible to develop an absolute prediction rule for atypical language representation at present. Instead, the figures presented in table 1 should be taken as a rough estimate of the predictive power of each of the factors associated with atypical language representation.

Handedness

One of the strongest predictors of language dominance is handedness. Studies have been consistent in demonstrating that atypical lateralisation is more frequent in left-handed than right-handed patients.^{7 15 27–30} In one study, 96% of right-handed patients showed left-hemisphere dominance and 4% right dominance. In comparison, 70% of left-handed or ambidextrous patients were left-hemisphere-dominant, with 15% bilateral and 15% right-dominant.¹⁵

In the normal population, there is also a correlation between the degree of atypical language and the degree of left-handedness.³⁹ In epilepsy patients, however, the correlation is stronger and a higher proportion of patients demonstrate a shift of both language and manual dominance to the right hemisphere.⁴⁰ Interestingly, left-handedness has also been reported in cases where lesions were remote from the motor cortex.^{26 40} It is still unclear what determines the representation of handedness, and how intertwined language and manual dominance are.

Lesion location

Various studies have addressed the role of lesion location in atypical language representation. Not all epilepsy is associated with structural lesions, but as most studies only provide data on the location of the lesion (and not the seizure focus), most information in this section concerns lesional epilepsy.

Left-hemispheric lesions are more frequently associated with atypical language than right-hemispheric lesions.^{6 27} Moreover, lesions in the left temporal or frontal lobes—where Wernicke's

Table 1 Factors associated with atypical language in epilepsy

Predictor	Proportion of patients with predictor with atypical language representation
Handedness	
Left-handedness	30%–70% ^{7 15 27–30}
Right-handedness	4%–26% ^{7 15 27–30}
Lesion location	
Left hemisphere	31%–38% ^{27 31}
Right hemisphere	7%–24% ^{27 31}
Left frontal or temporal lobe	32%–54% ^{32 33}
Left hippocampus	19%–43% ^{29 34 35}
Pathology	
Stroke	100% ^{18 30 36}
Hippocampal sclerosis	19%–43% ^{29 33–35 37}
Non-lesional epilepsy	30%–36% ^{18 30 31}
Small focal lesions, such as tumours, arteriovenous malformation, cortical dysplasia	13%–30% ^{18 30 33 34}
Epileptic activity	
High frequency of interictal epileptiform discharges	No percentages reported
NB: <i>Not</i> associated with seizure frequency, occurrence of generalised seizures, or duration of epilepsy	
Age at onset	
Young age at initial injury	36%–100% ^{1 32 35 36}
Young age at epilepsy onset	36%–51% ^{1 27 30 31 35 38}

and Broca's area reside—are more often associated with atypical language than lesions in other lobes.^{32 33} Within these lobes, however, the proximity of the lesion to the corresponding language area does not appear to correlate with atypical language,^{11 34 37 41} although such an effect, if subtle, could be concealed by small sample sizes. Since an essential characteristic of epileptic activity is its propagation, one could imagine that lesions could still affect language areas even if they are not directly adjacent to them.

A particularly strong case for such remote effects comes from evidence for the involvement of the hippocampus in atypical language. A common finding in epilepsy is hippocampal sclerosis (HS), which may be either a cause or a consequence of epilepsy. Studies that exclusively considered patients with left-sided HS found bilateral or right-dominant language in 19%–43% of individuals.^{29 34 35} Similar rates have been reported elsewhere.^{33 37 42} Besides hemispheric shifts, intrahemispheric changes in language representation are also found in HS patients.⁴³

The hippocampus could play a direct role in language processing, or it could lead to atypical language representation when seizures originate from it and then propagate to and disrupt classical language sites: two hypotheses that are not mutually exclusive.^{42 43} Support for the latter hypothesis comes from the finding that in patients with HS, the occurrence of sensory auras (auditory, vertiginous, somatosensory)—suggesting involvement of lateral temporal neocortex—were associated with atypical language, while psychic auras—suggesting mesolimbic spread—were associated with left dominance.²⁹

In the case of interhemispheric dissociation, one would intuitively predict that the language area closest to the lesion should shift to the contralateral hemisphere. In some cases of extra-temporal lesions, only the frontal language areas were transferred to the contralateral hemisphere.^{18 21} Strikingly, however, lesions in the temporal lobe can sometimes cause an interhemispheric shift of productive but not receptive language areas.¹⁷ It has therefore been suggested that frontal language networks may be more susceptible to interhemispheric compensation or reorganisation.^{17 18} However, there are also cases in which only temporal language areas show atypical lateralisation.^{13 14} Its rarity makes it difficult to draw firm conclusions regarding the relationship between lesion location and language representation in the case of interhemispheric dissociation.

Some observations suggest that hippocampal lesions are particularly likely to cause *interhemispheric* shifts, while lesions elsewhere result in *intra*hemispheric changes.^{26 34} Lesions close to Broca's area were associated with perilesional activity, while more remote lesions (of which three out of five were in the hippocampus) were associated with interhemispheric shifts.²⁶ However, HS is associated with both interhemispheric^{29 35 42} and intrahemispheric changes in language representation.⁴³

In summary, lesions relatively close to classical language areas are more frequently associated with atypical language organisation than more remote lesions. However, in line with the propagation of epileptic activity, lesions need not be directly adjacent to language sites, as is clear from the relationship between hippocampal lesions and atypical language. There is no conclusive evidence that allows for the prediction of atypical lateralisation versus intrahemispheric changes based on lesion location.

Pathology

Some types of pathology may be more closely associated with atypical language than others. It has been suggested that atypical lateralisation is more often associated with acquired

pathology than developmental pathology,^{36 41} although others did not find such a difference.^{32 33 37 38} This discrepancy might be explained by the fact that 'developmental' and 'acquired' are rather broad classifications. Acquired pathology can include, for example, stroke, inflammation or HS, while developmental pathology can include subtypes such as cortical dysplasia and glioneuronal tumours, pathological entities that are all quite different in nature. Moreover, this distinction is based on timing rather than specific pathology.

Early stroke affecting language areas almost invariably results in atypical language lateralisation.^{18 30 36} Logically, given the destructive nature of infarction, if a child speaks, language must have found another place to develop.³⁰

HS is associated with atypical language in about one in five cases.^{29 35 42} However, there is evidence that atypical language is not found so much in the *classic* cases of mesial temporal lobe epilepsy (including HS), but rather in more atypical cases. The nature and severity of the 'initial precipitating injury' that leads to HS seems to matter: atypical language is associated with atypical initial precipitating injuries (which included anything other than febrile seizures) and with EEG or MRI abnormalities extending beyond the hippocampal formation.³⁵ Moreover, it has been suggested that in HS, propagation of epileptic activity to the neocortex was associated with atypical language.²⁹ Last, given the various causes of HS, it is questionable whether HS should be considered as one pathological entity; its association with atypical language representation may be more related to the function or location of the hippocampus itself than to the type of pathology.

Curiously, small focal lesions—such as arteriovenous malformations, small tumours or local dysplasia—are less often associated with atypical language than non-lesional epilepsy.^{18 30 31 33 34} The cause of this remains unknown.

Epileptic activity

Functional aspects of epilepsy are also related to atypical language. Atypical language is correlated with frequent interictal epileptic activity.^{29 44} Moreover, the propagation pattern of epileptic activity is associated with atypical language representation: as described in the section Lesion location, propagation to the lateral temporal neocortex is associated with atypical language representation, while mesolimbic spread is not.²⁹ Further evidence that epileptic activity plays a direct role in language representation comes from a patient with left mesial temporal lobe epilepsy and right-dominant language, who showed a language shift to the left hemisphere after surgery that rendered her seizure-free.⁴⁵ In another case, a patient with left temporal lobe epilepsy showed right-dominant language after suffering from a bout of seizures, but showed bilateral activity (with left hemispheric dominance) 2 weeks later, when his seizure frequency had returned to normal.⁴⁶ This may have been due to compensation by the right hemisphere during suppression of the left hemisphere, although the authors find it more likely that the severe seizures may have uncoupled vascular responses from metabolism, preventing a rise in the fMRI BOLD signal.⁴⁶ These cases demonstrate that epileptic activity can have direct effects on language representation, but also suggest that the timing of imaging relative to epileptic activity may influence the results. In fact, many studies that address atypical language representation use fMRI. However, one important and fundamental limitation of fMRI is that lesions close to Broca's or Wernicke's area or those that are associated with a largely distorted normal anatomy may decrease fMRI lateralisation indices (termed 'fMRI critical lesions').⁴⁷ Thus, the number of

patients with atypical language representation is likely to be overestimated in such studies, especially when a large number of patients with fMRI critical lesions are included.

Interestingly, atypical language representation is associated with a high frequency of interictal discharges, but not with seizure frequency or the occurrence of generalised seizures.^{29–44} This suggests that chronic perturbation caused by interictal epileptic activity may be more important for changes in language representation than the acute stress of a seizure. One would also expect the duration of epilepsy to be associated with atypical language. Although such an effect has been occasionally reported,^{41–48} it has not been noted in most studies.^{10–18–29–33–44–49} This may be because plasticity is most likely to occur in a limited time window at a relatively young age (see the following section Age at onset). At the time of inclusion in a study, most patients will have had epilepsy for a long time. Thus, differences in the duration of epilepsy will primarily reflect the time which has passed *since* this window of opportunity, and hence would not be expected to have a major effect on language organisation. Moreover, a first seizure usually leads to a diagnosis of epilepsy, but patients may have had epileptiform activity for a long time before. Usually, therefore, the duration of abnormal brain activity cannot be reliably determined.

The involvement of particular brain structures during an epileptic insult can be inferred from ictal and post-ictal behaviour. The value of ictal and post-ictal language status for prediction of seizure focus and language localisation has been extensively reviewed.⁵⁰ This can also be used to identify patients with atypical language.⁵⁰ Post-ictal language was classified as 'discordant' when seizures originated from the left hemisphere but patients had relatively little post-ictal language impairment, or vice versa, if they originated from the right hemisphere and patients had much post-ictal language impairment. Patients with discordant post-ictal language patterns often had atypical language representation as shown by the Wada test.

Age at onset

Given that the brain is still in a process of maturation during childhood, it has been suggested that language reorganisation is more likely when brain injury occurs at a young age. Age at initial injury and age at epilepsy onset can be separated by many years and are discussed separately.

There is an association between young age at initial injury and atypical language representation.^{1–32–35–51} Duchowny *et al* reported that patients with acquired lesions only showed atypical language if the damage had occurred before they were 5 years old.³⁶ If age at initial injury and atypical language representation are inversely correlated, one would expect developmental lesions to be more closely associated with atypical language representation than acquired lesions. The absence of any differences between acquired and developmental lesions (see section on Pathology)^{32–33–37–38} may be explained by the fact that the acquired lesions were generally also sustained at a relatively young age.

Many studies have demonstrated an association between young age at seizure onset and atypical language.^{1–27–28–30–31–35–36–38–41} While the age of 6 is often used as the boundary between 'early' and 'late' onset,²⁷ the 'window of opportunity' for plasticity is not so concrete. There is a linear relationship between age at epilepsy onset and atypical language, suggesting that there is no particular age after which the potential for plasticity markedly decreases.¹ Rather, there is a gradual decline in the proportion of patients with atypical language. In patients with onset before 6 years, atypical language occurred in 50% of cases. For those with onset between 6 and 15 years this number fell to 28%.

Only after 15 years were the rates similar to controls (~5%). A similar gradual decline has been noted by others.³¹ An effect of age at seizure onset has also been reported for intrahemispheric variation in language organisation.²³

An association with age at seizure onset was not found in some other studies.^{7–10–18–29–32–33–37–44–48–49–51} Several explanations can be given for this discrepancy. First, some of the studies included patients with right hemisphere epilepsy, which does not usually lead to atypical language, and would therefore have weakened any possible associations.^{7–10–48–49} Second, some of the studies were limited by their small sample size.^{32–51} Of note, various studies that did not find an association with age at epilepsy onset included primarily or exclusively patients with HS.^{29–33–37–44} This might suggest that the hippocampus plays a direct role in language processing and that initial damage to the hippocampus may be more important for the development of atypical language representation than the timing of subsequent epilepsy.

CONCLUSIONS

In summary, in the normal population, there appears to be a spectrum of language lateralisation, with the majority of individuals positioned at the left-dominant end of the spectrum. In epilepsy, this continuum is shifted to the right. While relatively rare, the possibility of an interhemispheric dissociation of linguistic subfunctions (eg, receptive and productive language) should be appreciated. In addition, language representation can also be altered intrahemispherically. These different patterns of language representation are not necessarily mutually exclusive. It is usually unclear whether atypical language reflects compensation or reorganisation.

Of direct relevance to the clinician, the localisation of language cannot be established with a single language task^{16–22} due to the possibility of interhemispheric dissociation and because some linguistic subfunctions are represented atypically, while others are not. Moreover, it has become clear that localising language in one hemisphere does not rule out the presence of language in the contralateral hemisphere, in some cases necessitating bilateral Wada tests.

In the future, research should be directed at delineating the subtleties of patterns of atypical language, with particular attention paid to different linguistic subfunctions. FMRI studies with data-driven sorting approaches are sensitive to subtle inter-individual differences.^{10–18} Changes in the connectivity of language networks in epilepsy are also of great interest.

The literature on the predictors of atypical language is notoriously inconsistent, due to the heterogeneity of epilepsy. Nevertheless, it appears that atypical language is most likely when language areas are highly perturbed. More disruptive types of pathology are associated with atypical language; early stroke almost invariably leads to atypical language representation, in contrast to smaller circumscribed lesions such as arteriovenous malformations. Language areas can be directly perturbed if a lesion is in rough proximity, but in some cases, more remote lesions can interfere with language processing as well. This may be because: (1) white matter tracts in the language network are affected by the lesion; (2) epileptic activity from more remote locations may propagate to language areas; or (3) these remote locations have a direct function in language processing, as may be true of the hippocampus. Widespread and frequent interictal activity is associated with atypical language, whereas seizure frequency and the occurrence of generalised seizures are not. It would therefore appear that the language network is particularly vulnerable to chronic perturbation. In HS, atypical language is

more likely if a neocortical rather than mesolimbic spread of activity is presumed.²⁹ Language reorganisation only occurs if the brain is still sufficiently malleable. There is a gradual decline in the potential for plasticity with age, but no particular age after which plasticity becomes absolutely impossible.

Several predictors of atypical language have been described, making it possible to identify subgroups of patients that are most likely to show atypical language representation. The clinician could use this knowledge to decide to what extent costly and sometimes invasive language localisation procedures should be undertaken in a particular patient. Nevertheless, given the heterogeneous nature of the disease, the occasionally inconsistent literature and new insights into the subtleties of language organisation (such as interhemispheric dissociation), language localisation procedures remain essential to attain certainty in any given patient.

It can also not yet be predicted whether a patient will have undergone interhemispheric or intrahemispheric changes in language representation. This is related to the different instruments that were classically used to study both forms of atypical language representation: the Wada test (used to determine lateralisation) gives no information on intrahemispheric changes, while an electrode grid (used to study intrahemispheric organisation) is placed over only one hemisphere, precluding the study of lateralisation. In the future, large-scale imaging studies with fMRI or MEG, particularly when using data-driven sorting approaches,^{10 18} should provide the opportunity to study intrahemispheric and interhemispheric representation simultaneously. This could lead to the characterisation of different profiles of patients with intrahemispheric versus interhemispheric atypical language representation. Moreover, given the importance of the functional aspects of epilepsy,^{29 44} recording patterns of interictal activity with subdural electrodes may yield clues as to the effects of interictal activity on language organisation. Last, the presence or absence of atypical language representation depends on multiple factors that are often intercorrelated (eg, developmental tumour and young age at onset). To isolate the individual contributions of particular predictors and develop a clinically useful prediction rule, large-scale multi-centre studies are necessary to provide the statistical power for multivariate analysis. At the same time, the field could benefit from detailed case descriptions, in which individual patients are scrutinised in an attempt to explain observations that deviate from expectation.

Acknowledgements Many thanks to David Pritchett for reviewing the manuscript regarding language and style.

Contributors Both authors made substantial contributions to conception and design, acquisition, analysis and interpretation of data. The manuscript was drafted by KKD and critically revised for important intellectual content by CHF.

Competing interests None.

Provenance and peer review Not commissioned; externally peer reviewed.

REFERENCES

1. Springer JA, Binder JR, Hammeke TA, et al. Language dominance in neurologically normal and epilepsy subjects: a functional MRI study. *Brain* 1999;**122**:2033–46.
2. Knecht S, Deppe M, Dräger B, et al. Language lateralization in healthy right-handers. *Brain* 2000;**123**:74–81.
3. Price CJ. The anatomy of language: contributions from functional neuroimaging. *J Anat* 2000;**197**:335–59.
4. Knecht S, Dräger B, Flöel A, et al. Behavioural relevance of atypical language lateralization in healthy subjects. *Brain* 2001;**124**:1657–65.
5. Goldmann RE, Golby AJ. Atypical language representation in epilepsy: implications for injury-induced reorganization of brain function. *Epilepsy Behav* 2005;**6**:473–87.
6. Hamberger MJ, Cole J. Language organization and reorganization in epilepsy. *Neuropsychol Rev* 2011;**21**:240–51.
7. Müddel G, Lineweaver T, Schuele SU, et al. Atypical language lateralization in epilepsy patients. *Epilepsia* 2009;**50**:1505–16.
8. Monjaux C, Broadbent H, Boyd SG, et al. Language deficits and altered hemispheric lateralization in young people in remission from BECTS. *Epilepsia* 2011;**52**:e79–83.
9. Voets NL, Adcock JE, Flitney DE, et al. Distinct right frontal lobe activation in language processing following left hemisphere injury. *Brain* 2006;**129**:754–66.
10. You X, Adjouadi M, Guillen MR, et al. Sub-patterns of language network reorganization in pediatric localization related epilepsy: a multisite study. *Hum Brain Mapp* 2011;**32**:784–99.
11. Rosenberger LR, Zeck J, Berl MM, et al. Interhemispheric and intrahemispheric language reorganization in complex partial epilepsy. *Neurology* 2009;**72**:1830–6.
12. Labudda K, Mertens M, Janszky J, et al. Atypical language lateralisation associated with right fronto-temporal grey matter increases—a combined fMRI and VBM study in left-sided mesial temporal lobe epilepsy patients. *Neuroimage* 2012;**59**:728–37.
13. Moser DC, Papanicolaou AC, Swank P, et al. Evidence for the solidarity of the expressive and receptive language systems: a retrospective study. *J Int Neuropsychol Soc* 2011;**17**:62–8.
14. Kurthen M, Helmstaedter C, Linke DB, et al. Interhemispheric dissociation of expressive and receptive language functions in patients with complex-partial seizures: an amobarbital study. *Brain Lang* 1992;**43**:694–712.
15. Rasmussen T, Milner B. The role of early left-brain injury in determining lateralization of cerebral speech functions. *Ann N Y Acad Sci* 1977;**299**:355–69.
16. Rutten GJ, Ramsey NF, van Rijen PC, et al. fMRI-determined language lateralization in patients with unilateral or mixed language dominance according to the Wada test. *Neuroimage* 2002;**17**:447–60.
17. Lee D, Swanson SJ, Sabsevitz DS, et al. Functional MRI and Wada studies in patients with interhemispheric dissociation of language functions. *Epilepsy Behav* 2008;**13**:350–6.
18. Mbwana J, Berl MM, Ritzl EK, et al. Limitations to plasticity of language network reorganization in localization related epilepsy. *Brain* 2009;**132**:347–56.
19. Tracy JI, Waldron B, Glosser D, et al. Hemispheric lateralization and language skill coherence in temporal lobe epilepsy. *Cortex* 2009;**45**:1178–89.
20. Gage NM, Eliashiv DS, Isenberg AL, et al. Rethinking clinical language mapping approaches: discordant receptive and expressive hemispheric language dominance in epilepsy surgery candidates. *J Clin Neurophysiol* 2011;**28**:278–88.
21. Kamada K, Takeuchi F, Kuriki S, et al. Dissociated expressive and receptive language functions on magnetoencephalography, functional magnetic resonance imaging, and amobarbital studies. Case report and review of the literature. *J Neurosurg* 2006;**104**:598–607.
22. Wilke M, Pieper T, Lindner K, et al. Why one task is not enough: functional MRI for atypical language organization in two children. *Eur J Paediatr Neurol* 2010;**14**:474–8.
23. Schwartz TH, Devinsky O, Doyle W, et al. Preoperative predictors of anterior temporal language areas. *J Neurosurg* 1998;**89**:962–70.
24. Kadis DS, Iida K, Kerr EN, et al. Intrahemispheric reorganization of language in children with medically intractable epilepsy of the left hemisphere. *J Int Neuropsychol Soc* 2007;**13**:505–16.
25. Seghier ML, Lazeyras F, Pegna AJ, et al. Group analysis and the subject factor in functional magnetic resonance imaging: analysis of fifty right-handed healthy subjects in a semantic language task. *Hum Brain Mapp* 2008;**29**:461–77.
26. Liégeois F, Connelly A, Cross JH, et al. Language reorganization in children with early-onset lesions of the left hemisphere: an fMRI study. *Brain* 2004;**127**:1229–36.
27. Saltzman-Benaiah J, Scott K, Smith ML. Factors associated with atypical speech representation in children with intractable epilepsy. *Neuropsychologia* 2003;**41**:1967–74.
28. Gleissner U, Kurthen M, Sassen R, et al. Clinical and neuropsychological characteristics of pediatric epilepsy patients with atypical language dominance. *Epilepsy Behav* 2003;**4**:746–52.
29. Janszky J, Jokeit H, Heinemann D, et al. Epileptic activity influences the speech organization in medial temporal lobe epilepsy. *Brain* 2003;**126**:2043–51.
30. Gaillard WD, Berl MM, Moore EN, et al. Atypical language in lesional and nonlesional complex partial epilepsy. *Neurology* 2007;**69**:1761–71.
31. Helmstaedter C, Kurthen M, Linke DB, et al. Patterns of language dominance in focal left and right hemisphere epilepsies: relation to MRI findings, EEG, sex, and age at onset of epilepsy. *Brain Cogn* 1997;**33**:135–50.
32. Anderson DP, Harvey AS, Saling MM, et al. fMRI lateralization of expressive language in children with cerebral lesions. *Epilepsia* 2006;**47**:998–1008.
33. Korman B, Bernal B, Duchowny M, et al. Atypical propositional language organization in prenatal and early-acquired temporal lobe lesions. *J Child Neurol* 2010;**25**:985–93.
34. Pataraja E, Simos PG, Castillo EM, et al. Reorganization of language-specific cortex in patients with lesions or mesial temporal epilepsy. *Neurology* 2004;**23**:1825–32.
35. Rathore C, George A, Kesavadas C, et al. Extent of initial injury determines language lateralization in mesial temporal lobe epilepsy with hippocampal sclerosis (MTLE-HS). *Epilepsia* 2009;**50**:2249–55.
36. Duchowny M, Jayakar P, Harvey AS, et al. Language cortex representation: effects of developmental versus acquired pathology. *Ann Neurol* 1996;**40**:31–8.

37. **Briellmann RS**, Labate A, Harvey AS, *et al.* Is language lateralization in temporal lobe epilepsy patients related to the nature of the epileptogenic lesion? *Epilepsia* 2006;**47**:916–20.
38. **Kadis DS**, Kerr EN, Rutka JT, *et al.* Pathology type does not predict language lateralization in children with medically intractable epilepsy. *Epilepsia* 2009;**50**:1498–504.
39. **Knecht S**, Drager B, Deppe M, *et al.* Handedness and hemispheric language dominance in healthy humans. *Brain* 2000;**123**:2512–18.
40. **Sveller C**, Briellmann RS, Saling MM, *et al.* Relationship between language lateralization and handedness in left-hemispheric partial epilepsy. *Neurology* 2006;**67**:1813–17.
41. **Hadac J**, Brozova K, Tintera J, *et al.* Language lateralization in children with pre- and postnatal epileptogenic lesions of the left hemisphere: an fMRI study. *Epileptic Disord* 2007;**9**(Suppl 1):S19–27.
42. **Weber B**, Wellmer J, Reuber M, *et al.* Left hippocampal pathology is associated with atypical language lateralization in patients with focal epilepsy. *Brain* 2006;**129**:346–51.
43. **Hamberger MJ**, Seidel WT, Goodman RR, *et al.* Evidence for cortical reorganization of language in patients with hippocampal sclerosis. *Brain* 2007;**130**:2942–50.
44. **Janszky J**, Mertens M, Janszky I, *et al.* Left-sided interictal epileptic activity induces shift of language lateralization in temporal lobe epilepsy: an fMRI study. *Epilepsia* 2006;**47**:921–7.
45. **Helmstaedter C**, Fritz NE, Gonzalez Perez PA, *et al.* Shift-back of right into left hemisphere language dominance after control of epileptic seizures: evidence for epilepsy driven functional cerebral organization. *Epilepsy Res* 2006;**70**:257–62.
46. **Jayakar P**, Bernal B, Santiago Medina L, *et al.* False lateralization of language cortex on functional MRI after a cluster of focal seizures. *Neurology* 2002;**58**:490–2.
47. **Wellmer J**, Weber B, Urbach H, *et al.* Cerebral lesions can impair fMRI-based language lateralization. *Epilepsia* 2009;**50**:2213–24.
48. **Yuan W**, Szafarski JP, Schmithorst VJ, *et al.* fMRI shows atypical language lateralization in pediatric epilepsy patients. *Epilepsia* 2006;**47**:593–600.
49. **Thivard L**, Hombrouck J, du Montcel ST, *et al.* Productive and perceptive language reorganization in temporal lobe epilepsy. *Neuroimage* 2005;**24**:841–51.
50. **Privitera M**, Kim KK. Postictal language function. *Epilepsy Behav* 2010;**19**:140–5.
51. **Brázdil M**, Chlebus P, Mikl M, *et al.* Reorganization of language-related neuronal networks in patients with left temporal lobe epilepsy? an fMRI study. *Eur J Neurol* 2005;**12**:268–75.

Copyright of Journal of Neurology, Neurosurgery & Psychiatry is the property of BMJ Publishing Group and its content may not be copied or emailed to multiple sites or posted to a listserv without the copyright holder's express written permission. However, users may print, download, or email articles for individual use.